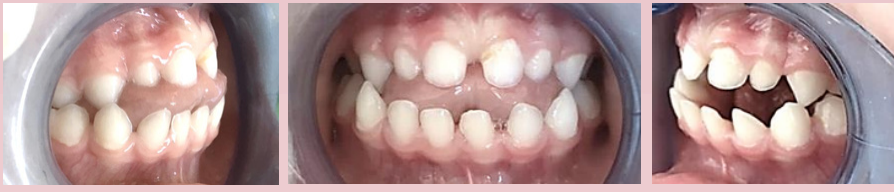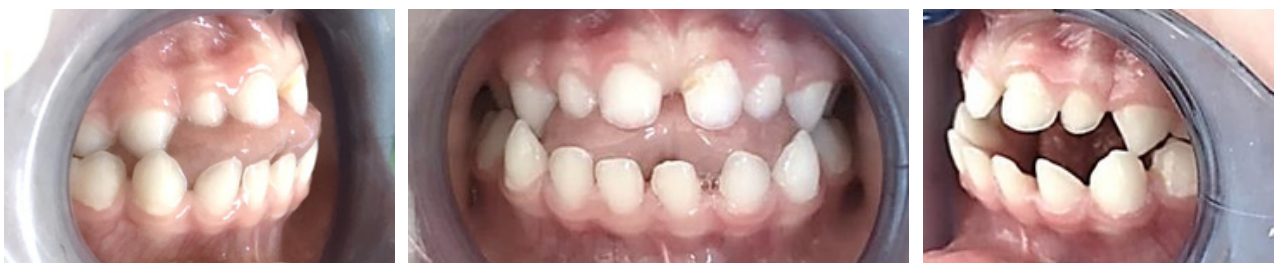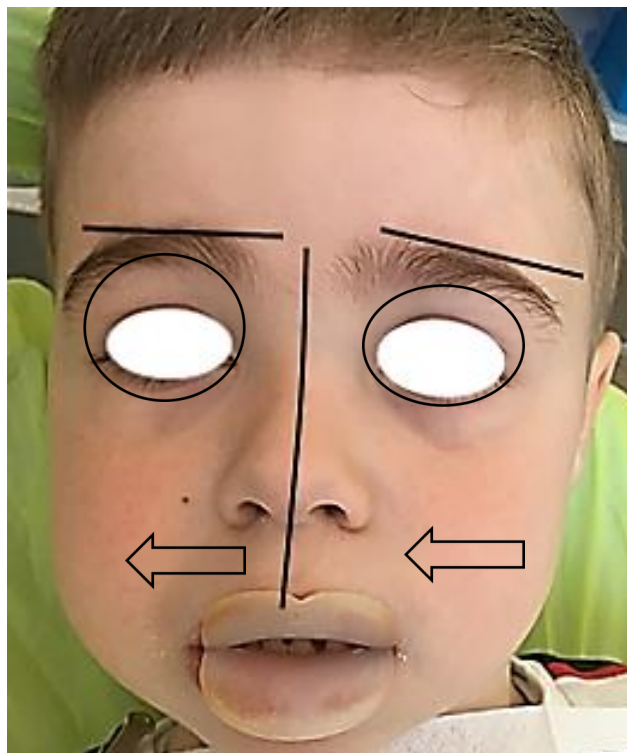


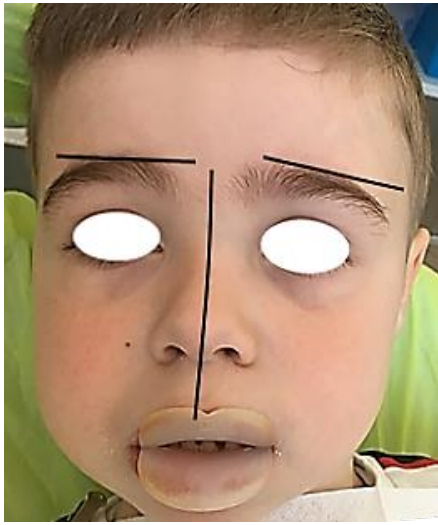
**OPEN BITE AND  
CRANIOFACIAL ASYMMETRY**

Dr. Pietro Manzini

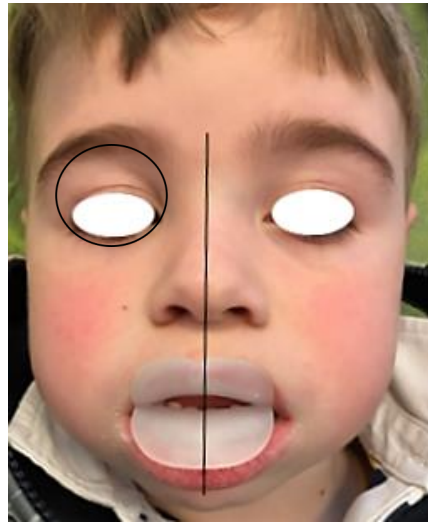


THE 5-YEAR-OLD MALE PATIENT PRESENTS AN OPEN BITE AND  
CRANIOFACIAL ASYMMETRY.  
THE USE OF FROGGMOUTH IS PRESCRIBED.

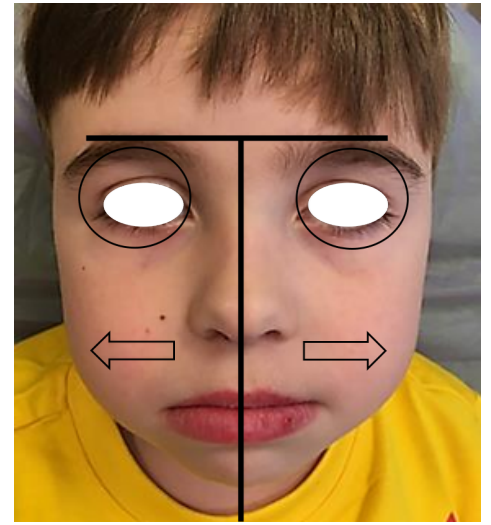




START OF TREATMENT

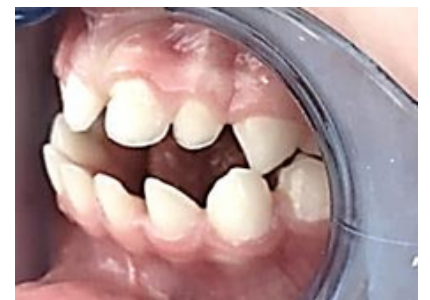
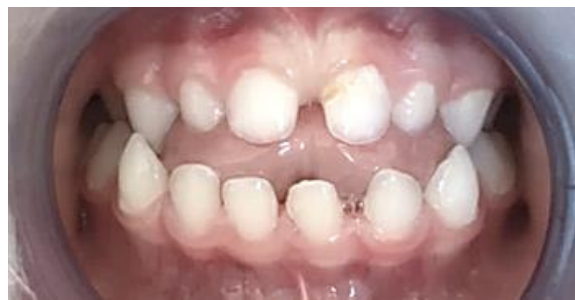
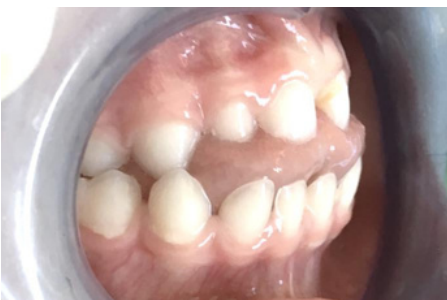5 MONTHS LATER

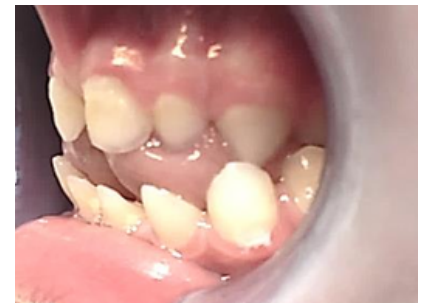
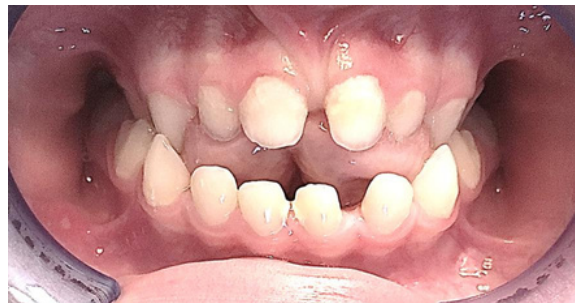
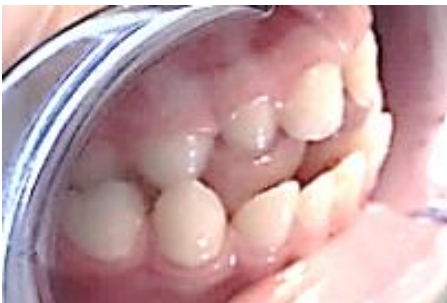12 MONTHS LATER

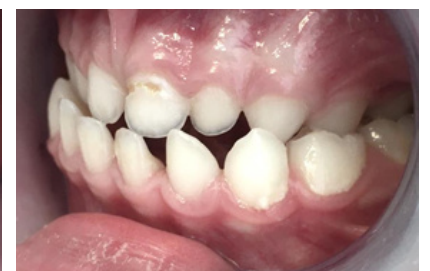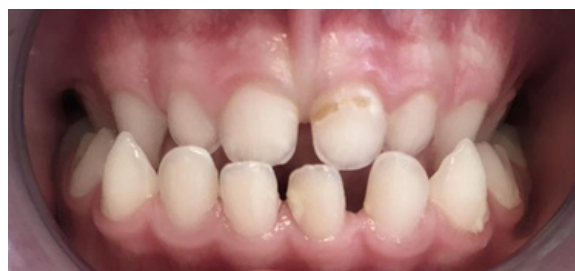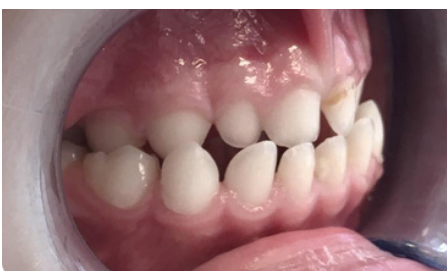START OF TREATMENT



5 MONTHS LATER



12 MONTHS LATER



AFTER 12 MONTHS OF TREATMENT, CRANIOFACIAL SYMMETRY HAS BEEN RESTORED, OPEN BITE AND TONGUE POSTURE HAVE BEEN CORRECTED.



FROGGY MOUTH